



## PATIENT PRESENTING CLINICAL SIGNS

**PATIENT** Molly Davis  
**SPECIES** Patient was seen today for an advanced dental procedure for extraction of complicated crown root fracture #108. During the pre-sedation physical examination, a 2/6 heart murmur was auscultated and chest radiographs prior to anesthesia was recommended. Patient's owner has a boarding facility and brings patient to work almost everyday. No history of travel. Patient is on Bravecto. No notable coughing or sneezing. Patient will hack very rarely, but nothing owner seems notable.  
**SPECIES** Canine  
Abnormal PE/Chem/CBC/UA Results: RBC 9.25, Hgb 20.7, Reticulocytes 123. Chem WNL

## RADIOGRAPHIC STUDY OF THE THORAX

**BREED** Right/left lateral and ventrodorsal views of the thorax totaling three images available for review. The DV view is flipped.  
**BREED** Shar Pei

## RADIOGRAPHIC FINDINGS

**SEX** The vertebral heart score is 9.8. The cardiac silhouette presents within normal radiographic limits.

**FS** There is no radiographic evidence of structural cardiac remodeling or overall cardiomegaly. No specific chamber enlargement is noted.

**AGE** The pulmonary vasculature appears normal. Mild increase in bronchial wall markings, likely age-related and incidental, is noted. There is no evidence of pulmonary edema, consolidation or nodular disease.  
**AGE** 4

**INTERPRETED BY** The trachea is normal in position and diameter on the right and left lateral views.

Nele Eley (Ondreka),  
DVM Dr. med. vet.,  
DipECVDI

The mediastinal silhouette presents within normal limits.

The thoracic boundaries are within normal limits.

## HOSPITAL NAME RADIOGRAPHIC DIAGNOSIS

**HOSPITAL NAME** Green Dog Dental

- Mild bronchial wall thickening, likely age-related.
- No evidence of active lower airway disease.
- Normal radiographic presentation of the heart with vertebral heart score within normal limits.

## REFERRING VET INTERPRETATION OF FINDINGS & FURTHER RECOMMENDATIONS

**REFERRING VET** Dr Habawel  
There is no radiographic evidence of cardiomegaly or structural cardiac remodeling and no signs of thoracic compromise that would contraindicate anesthesia are seen. Proceed with planned dental procedure.

**INVOICE** Routine monitoring of cardiac murmur and echocardiography may be considered if murmur changes or clinical signs develop.  
22947

## DATE

11/12/2025



## PATIENT

Molly Davis

## SPECIES

Canine

## BREED

Shar Pei

## SEX

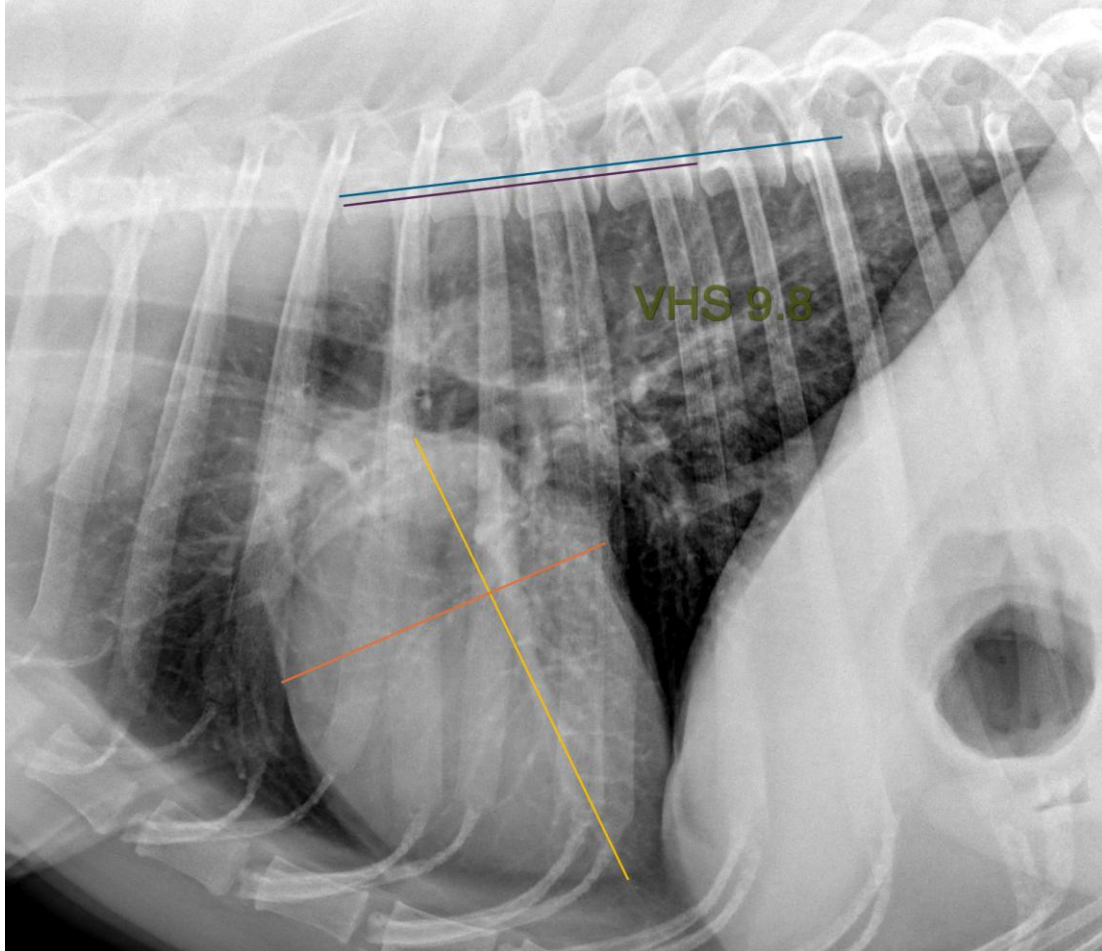
FS

## AGE

4

## INTERPRETED BY

Nele Eley (Ondreka),  
DVM Dr. med. vet.,  
DipECVDI



## HOSPITAL NAME

Green Dog Dental

The information and recommendations provided are based on the images presented by the referring veterinarian. No evaluation can be communicated regarding pathology that was not visible in the image/video clips provided.

## REFERRING VET

Dr Habawel

Thank you for this referral. If the clinical or image interpretation does not parallel your findings or if I can be of any further assistance please contact me.

## INVOICE

22947

Nele Eley (Ondreka), DVM, Dr. med. vet., DipECVDI  
European Specialist in Veterinary Diagnostic Imaging, Cert. Radiology,  
Senior lecturer University of Giessen/Germany, Veterinary Faculty, Department of Radiology.  
[info@sonopath.com](mailto:info@sonopath.com)

## DATE

11/12/2025



## PATIENT

Molly Davis

## SPECIES

Canine

## BREED

Shar Pei

## SEX

FS

## AGE

4

## INTERPRETED BY

Nele Eley (Ondreka),  
DVM Dr. med. vet.,  
DipECVDI

## HOSPITAL NAME

Green Dog Dental

## REFERRING VET

Dr Habawel

## INVOICE

22947

## DATE

11/12/2025